

---

**RESEARCH ARTICLE**

## An Incidental Finding of Chilaiditi's Sign: A Case Report

Lana Dardari<sup>1</sup> ✉ Maher Taha<sup>2</sup>, Ali Haider<sup>3</sup>, Fatima Faqih<sup>4</sup> and Omar Sharif<sup>5</sup>

<sup>12</sup>MB BCh BAO, California Institute of Behavioral Neurosciences & Psychology, Fairfield, California, United States of America

<sup>34</sup>MD, Internal Medicine, King Hamad University Hospital, Busaiteen, Bahrain

<sup>5</sup>MD, Gastroenterology, King Hamad University Hospital, Busaiteen, Bahrain

**Corresponding Author:** Lana Dardari, **E-mail:** [lanadardari@gmail.com](mailto:lanadardari@gmail.com)

---

**ABSTRACT**

Chilaiditi's Sign is a rare radiographic finding in which there is an interposition of the colon between the diaphragm and the liver. The etiology is multifactorial and can be divided into diaphragmatic, hepatic, and colonic causes. Chilaiditi's sign is considered a cause of pseudo-pneumoperitoneum. On imaging, the sign can easily be misdiagnosed as a 'true' pneumoperitoneum, causing the patient to undergo unnecessary investigations and interventions. This case report presents an 88-year-old male with a past medical history of Ischemic Heart Disease (IHD) and Hypertension (HTN) who presented to the Emergency Department (ED) with a clinical picture of obstructive jaundice and was admitted for an Endoscopic Retrograde Cholangiopancreatography (ERCP). Post-ERCP, the patient complained of chest pain, in which a chest X-ray was done, and Chilaiditi's sign was found.

**KEYWORDS**

Pneumoperitoneum, Pseudo-pneumoperitoneum, Chilaiditi's sign, Chilaiditi's syndrome, Case report

**ARTICLE INFORMATION**

**ACCEPTED:** 01 September 2023

**PUBLISHED:** 07 September 2023

**DOI:** 10.32996/jmhs.2023.4.5.1

---

**1. Introduction**

Chilaiditi's sign is a rare and benign radiological finding in which there is an anterior interposition of the colon (most commonly the transverse colon) between the liver and the hemidiaphragm [Moaven, 2012]. It is often detected incidentally on plain radiographs; findings include the presence of air below the right hemidiaphragm and gas within the bowel, suggesting that the air is not within the peritoneum, which is regarded as a pseudo-pneumoperitoneum. Chilaiditi's sign can also be detected on ultrasound. Some important findings suggest a lack of impact from body position change on air echo, the gas surface being distant in relation to the diaphragmatic peritoneum, an uneven gas surface distribution, and the presence of colonic haustra [Moaven, 2012; Smereczyński, 2015]. If findings on plain radiograph and ultrasound are inconclusive, a computed tomography (CT) scan [Moaven, 2012; Smereczyński, 2015, Mistry, 2017] can confirm the findings of interposed colonic loops between the right hemidiaphragm and liver with no free intraperitoneal air [Chilaiditi syndrome, 2021].

It is important to distinguish a pseudo-pneumoperitoneum from a 'true' pneumoperitoneum due to the significant differences in management. The former may be treated conservatively, whereas the latter may require more urgent and invasive investigations and treatment [Moaven, 2012; Smereczyński, 2015, Mistry, 2017, Lo, 2010, Ghani 2017]. Correctly distinguishing between the two prevents physicians from proceeding with unnecessary referrals, investigations, and treatment.

This report presents a case in which a patient had an incidental finding of Chilaiditi's sign on a chest radiograph while undergoing investigations for post endoscopic retrograde cholangio pancreatography (ERCP) chest pain. This case report aims to highlight the findings of Chilaiditi's sign, the importance of recognizing it as a pseudo pneumoperitoneum, management, and a brief discussion of Chilaiditi's syndrome.

## **2. Case Presentation**

An 88-year-old male presented to the emergency department (ED) of King Hamad University Hospital in Busaiteen, Bahrain, with a five day history of yellow discoloration in his eyes and reduced oral intake. He denied any history of abdominal pain, nausea or vomiting, altered bowel habits, and fever. He has a past medical history of Ischemic Heart Disease (IHD) and Hypertension (HTN). Surgical history is significant for undergoing a Coronary Artery Bypass Graft (CABG) seven years ago, as well as an L1-L3 spinal fixation. Family and social history were insignificant. Current medications include Bisoprolol, Aspirin, Insulin Glargine, Insulin Aspart, and Atorvastatin, and they are under cardiology follow-up. On examination, the patient was vitally stable, the abdomen was soft and non-tender, and no signs of guarding, rigidity, or rebound tenderness were noted. The patient was evaluated for obstructive jaundice in the ED, and blood was sent for routine investigations, which returned with deranged liver function tests (LFTs).

The patient was admitted to the hospital under the impression of obstructive jaundice and was scheduled for an ERCP under sedation and monitoring of LFTs. The patient underwent magnetic resonance cholangiopancreatography (MRCP) and ERCP under sedation, revealing strictures in the duodenum and distal common bile duct. Post-ERCP, the patient experienced chest pain and shivering. At that point, he was reviewed and underwent a Chest X-Ray (CXR), electrocardiogram (ECG), Abdominal X-Ray, and blood work for cardiac enzymes and renal function tests.

Chest radiograph (Figure 1) demonstrated an elevated right hemidiaphragm with the presence of gas-filled bowel loops intrapositioned between the right hemidiaphragm and liver. The plain film of the abdomen (Figure 2) showed no signs of 'true' pneumoperitoneum. Additionally, the MRCP that was done for the patient while undergoing an ERCP demonstrated Chilaiditi's sign (Figures 3-8). Recognizing this as a benign finding, as well as considering that the patient was not showing signs or symptoms of bowel obstruction and/or perforation, prevented this patient from undergoing further investigations and invasive procedures. Therefore, the focus of management was shifted towards managing the patient's current cardiac symptoms and ruling out a more sinister disease due to his medical history.

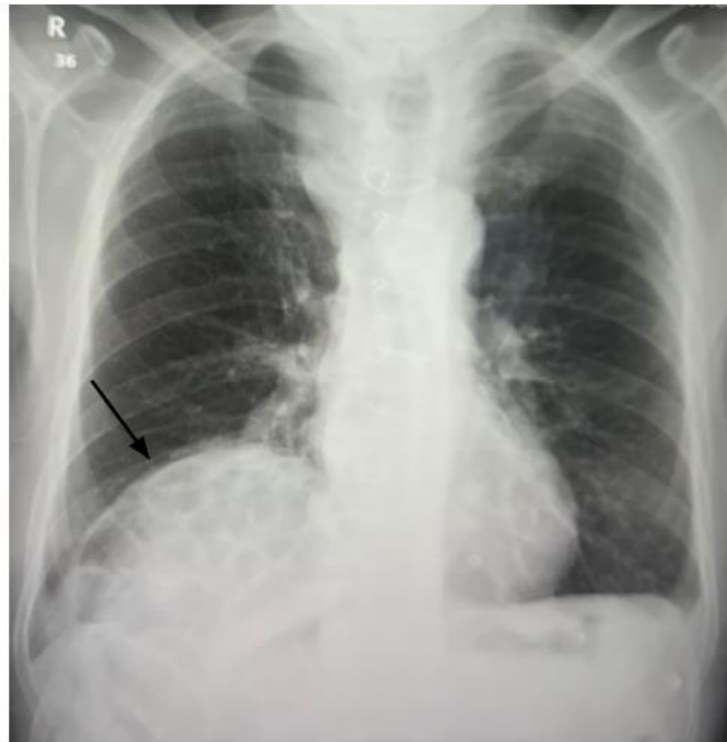

Figure 1. Plain Chest X-ray demonstrating the appearance of haustral folds (marked by the black arrow), indicating the gas is confined within the bowel. The gas-filled bowel loop is between the right hemidiaphragm and liver, confirming Chilaiditi's sign.

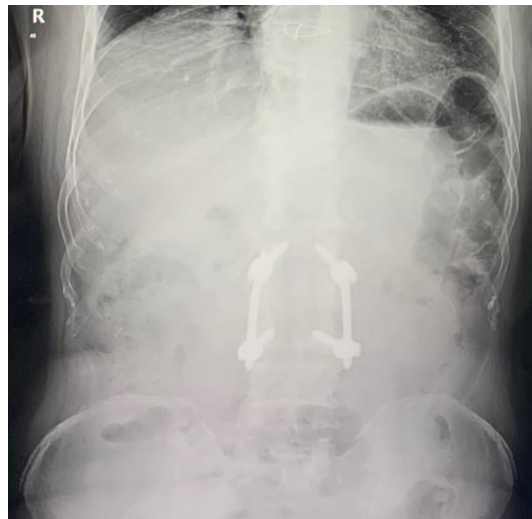

Figure 2. Plain film of the abdomen. No pneumoperitoneum was seen. There are no multiple significantly dilated air-fluid levels. Colonic fecal and gas content. Other findings include: Internal biliary/Common bile duct stent. Reduced bone density appreciated. L1 - L3 spinal fixation and sternotomy sutures.

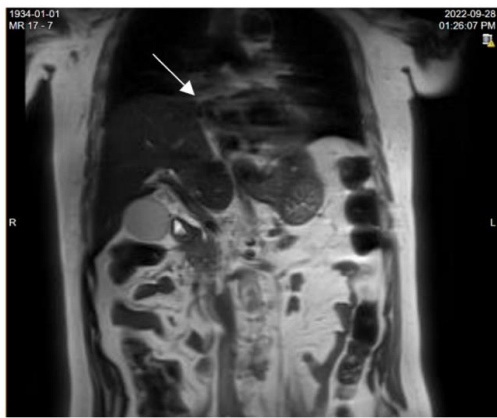


Figure 3

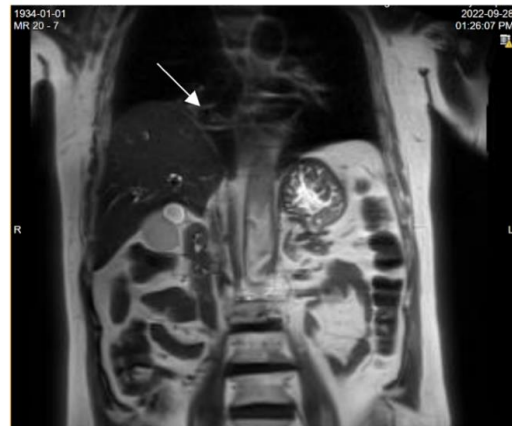

Figure 4

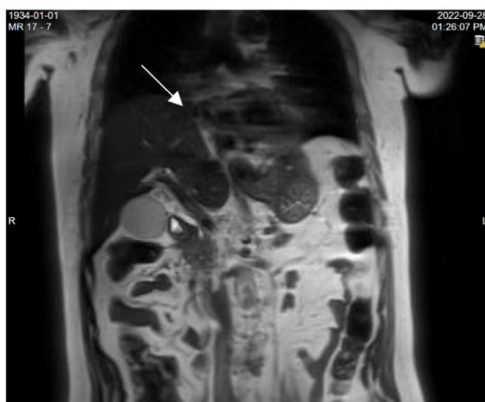


Figure 5

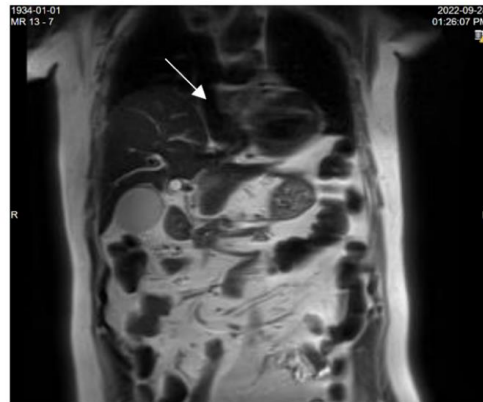


Figure 6

Figure 3-6. Coronal view MRCP showing the presence of interposed colonic loops between the right hemidiaphragm and liver with no free intraperitoneal air (White arrow).

### **3. Discussion**

Chilaiditi's sign is a rare anomaly seen on chest or abdominal radiographs with an incidence of 0.0025 - 0.28% [Alva, 2008]. This case report described a patient where Chilaiditi's sign was found incidentally while investigating for causes of chest pain post-ERCP. It is important to note Chilaiditi's sign when it presents with symptoms; it can be referred to as Chilaiditi's syndrome, in which management differs. Chilaiditi's syndrome presents with abdominal pain, anorexia, nausea, vomiting, constipation, changes in bowel habits, signs of obstruction, respiratory distress, and angina-like chest pain [Smereczyński, 2015]. In rare cases, a combination of these multiorgan symptoms is observed [Fisher, 2003]. Chilaiditi's syndrome will be described in further detail below.

The pathogenesis of Chilaiditi's sign can be divided into three entities- diaphragmatic, hepatic, or colonic pathologies, that increase the risk of developing the sign and syndrome. Diaphragmatic causes include any pathology that raises the diaphragm, causing an increase in the space between the diaphragm and the liver. Examples include phrenic nerve palsy, causing a right-sided diaphragmatic hemiparesis. Another example would be a congenital loss of muscular fibers of the diaphragm, causing thinning of a portion or all of the diaphragm as the muscle has been replaced by fibroelastic tissue [Gulati, 2008]. Hepatic pathologies include the loss of tone of the falciform ligament, as it normally functions to connect the liver to the abdominal wall and diaphragm. Cirrhosis or hepatectomy results in a smaller liver, causing an increased distance between the liver and diaphragm, predisposing to Chilaiditi's sign [Cawich, 2017]. Colonic causes include dolichocolon, an abnormally long large intestine, where the extra length can cause it to interpose itself between the liver and diaphragm [Mistry, 2017]. An increase in abdominal pressure, as found in obesity and ascites, has been associated with an increased risk of developing Chilaiditi's sign [Cawich, 2017]. Patients who develop adhesions due to abdominal surgery are at an increased risk, as the fibrous tissue bands can form between the liver and diaphragm, facilitating the colon's interposition [Fiumecaldo, 2018]. Absence, laxity, or elongation of the suspensory ligaments of the transverse colon also increases the risk [Moaven, 2012]. Of these factors, dolichocolon and laxity of the falciform and suspensory ligaments (of the transverse colon) are the main predisposing factors causing Chilaiditi's sign and syndrome [Raker, 2023].

Chilaiditi's sign is considered a pseudo-pneumoperitoneum, meaning that there is an appearance of free intraperitoneal gas when it is actually contained within an organ. Differentiating between a 'true' pneumoperitoneum and pseudo-pneumoperitoneum is significant due to the differences in management and their respective complications. Important differentials of Chilaiditi's sign include pneumoperitoneum and subphrenic abscess. However, to distinguish between Chilaiditi's sign and a 'true' pneumoperitoneum, identifying the colon through haustral markings and normal plicae circulares can help rule out more serious entities [Moaven, 2012]. Differentials for pseudo-pneumoperitoneum include; basal linear atelectasis, pneumomediastinum, pseudo-Rigler's sign, diaphragmatic undulation, biliary, portal vein or bowel wall gas, fat within the subdiaphragmatic space, and benign post-traumatic pseudo-pneumoperitoneum [Pseudopneumoperitoneum, 2023]. Patients with an isolated finding of Chilaiditi's sign are often asymptomatic and require no intervention, and management is conservative [Chilaiditi syndrome, 2021]. If the sign is accompanied by symptoms, Chilaiditi's syndrome is impressed, which is discussed further below.

Chilaiditi's syndrome presents with Chilaiditi's signs alongside symptoms, such as abdominal pain, nausea, vomiting, and anorexia; a diagnosis of Chilaiditi syndrome is made [Chen, 2016]. Due to the non-specific symptoms, the differential diagnosis can include bowel obstruction, volvulus, intussusception, ischemic bowel, appendicitis, or diverticulitis. It can also be misdiagnosed as a diaphragmatic hernia. Physicians should first rule out the more severe causes of pneumoperitoneum, such as bowel perforation, as a misdiagnosis can lead to unnecessary surgical intervention and complications [Moaven, 2012]. Another example of an unnecessary intervention may be that a physician chooses a diagnostic procedure such as a colonoscopy; however, there is an increased risk of bowel perforation in Chilaiditi's syndrome [Gurvits, 2009].

Complications of Chilaiditi's syndrome can include volvulus of the cecum, splenic flexure or transverse colon, and bowel perforation. Respiratory distress and less frequently angina-like chest pain can also be seen in some patients. As in any other case, a timely diagnosis and the correct course of management are crucial. Initial management of Chilaiditi's syndrome should include bed rest, intravenous fluid therapy, bowel decompression, enemas, and laxatives. Repeat radiographs following decompression may show the disappearance of the air below the diaphragm and the resolution of Chilaiditi's sign and syndrome [Moaven, 2012]. Surgical intervention is indicated if the patient does not respond to initial conservative management and the obstruction has failed to resolve or if there is evidence of bowel ischemia. The more favorable surgical intervention varies from case to case and which section of the bowel is interposed.

### **4. Conclusions**

The objective of this case report is to emphasize that due to the overlapping of non-specific signs and symptoms often seen in the medical field, it is important to make a correct diagnosis in a timely manner, such as in the case of a 'true' pneumoperitoneum

versus a pseudo-pneumoperitoneum, due to the radical differences in management and intervention. Identifying Chilaiditi's sign, such as in this case, prevents clinicians from making unnecessary referrals and patients from undergoing unnecessary investigations and procedures. It is important for clinicians to ensure that the patient's signs and symptoms are consistent with radiographic findings. In this case, the patient was being investigated for symptoms suggesting an underlying cardiac pathology, which led to the incidental finding of Chilaiditi's sign. This case report highlighted that correctly identifying Chilaiditi's sign as a benign pathology and taking the patient's symptoms into consideration prevented unnecessary investigations and procedures the patient may have undergone to rule out a more serious pathology. Further studies on the signs and symptoms of Chilaiditi's syndrome should be undertaken in order to establish the incidence and prevalence, diagnostic criteria, symptomatology, surgical versus conservative management, and long term complications.

### Ethics Statement and Conflict of Interest Disclosures

**Human subjects:** All authors have confirmed that this study did not involve human participants or tissue. **Conflicts of interest:** In compliance with [the ICMJE uniform disclosure form](#), all authors declare the following: **Payment/services info:** All authors have declared that no financial support was received from any organization for the submitted work. **Financial relationships:** All authors have declared that they have no financial relationships at present or within the previous three years with any organizations that might have an interest in the submitted work. **Other relationships:** All authors have declared that there are no other relationships or activities that could appear to have influenced the submitted work.

**Acknowledgements:** MT contributed to the initial draft of the manuscript. AH and FF helped with the introduction and case presentation sections. OS was our mentor who provided valuable insights and expertise during the development of the discussion section. All authors read and approved the final manuscript.

### References

- [1] Alva S (2008). Image of the month—quiz case. Arch Surg, 143:94. [10.1001/archsurg.2007.12-b](https://doi.org/10.1001/archsurg.2007.12-b)
- [2] Chilaiditi syndrome. (2021). Accessed: 05/08/2023: <https://radiopaedia.org/articles/chilaiditi-syndrome>.
- [3] Chen S.Y, Chen N.F, Lu C.S (2016). [Chilaiditi syndrome](#). QJM, 109:625-6. [10.1093/qjmed/hcw102](https://doi.org/10.1093/qjmed/hcw102)
- [4] Cawich SO, Spence R, Mohammed F, Gardner MT, Sinanan A, Naraynsingh V (2017). [The liver and Chilaiditi's syndrome: Significance of hepatic surface grooves](#). SAGE Open Medical Case Reports. 2017, 5:[10.1177/2050313X17744979](https://doi.org/10.1177/2050313X17744979)
- [5] Fisher AA (2003). [An elderly man with chest pain, shortness of breath, and constipation](#). Postgrad Med J. 2003, 79:180-184. [10.1136/pmj.79.929.180](https://doi.org/10.1136/pmj.79.929.180)
- [6] Fiumecaldo D, Buck L (2018). [Chilaiditi's syndrome causing high-grade small-bowel obstruction requiring exploratory laparotomy](#). Mil. Med, 183:281- 283. [10.1093/milmed/usx069](https://doi.org/10.1093/milmed/usx069)
- [7] Gurvits GE, Lau N, Gualtieri N, Robilotti JG (2009). [Air under the right diaphragm: Colonoscopy in the setting of Chilaiditi syndrome](#). Gastrointest. Endosc. 2009, 69:758-9. [10.1016/j.gie.2008.12.238](https://doi.org/10.1016/j.gie.2008.12.238)
- [8] Ghani S, Course CW, Bodla HP (2017). [From sign to syndrome: Chilaiditi](#). Arch. Dis. Child. 2017, 102:11-17. [10.1136/archdischild-2017-313467](https://doi.org/10.1136/archdischild-2017-313467)
- [9] Gulati MS, Wafula J, Aggarwal S (2008). [Chilaiditi's sign possibly associated with malposition of chest tube placement](#). J. Postgrad. Med, 54:138-139. [10.4103/0022-3859.40781](https://doi.org/10.4103/0022-3859.40781)
- [10] Lo BM (2010). Radiographic look-alikes: Distinguishing between pneumoperitoneum and pseudopneumoperitoneum. J. Emerg. Med, 38:36-39. [10.1016/j.jemermed.2008.01.011](https://doi.org/10.1016/j.jemermed.2008.01.011)
- [11] Moaven O, Hodin RA (2012). [Chilaiditi syndrome: A rare entity with important differential diagnoses](#). Gastroenterol Hepatol, 8:276-278.
- [12] Mistry KA, Bhoil R, Kumar N, Chopra R, Thapar N (2017). [Significance of chilaiditi sign and chilaiditi syndrome](#). Emerg Nurse, 25:26-31. [10.7748/en.2017.e1682](https://doi.org/10.7748/en.2017.e1682)
- [13] Raker EJ, Plorde JJ (2023). [Transverse colon volvulus and associated Chilaiditi's Syndrome: Case report and literature review](#). Am. J. Gastroenterol. 1996, 91:2613-6.
- [14] Pseudopneumoperitoneum. (2023). Accessed:
- [15] Smereczyński A, Kołaczyk K. (2015). [Is it possible to differentiate between pseudopneumoperitoneum and similar pathologies ultrasonographically?](#) J. Ultrason. 2015, 17:30 - 35. [10.15557/jou.2017.0004](https://doi.org/10.15557/jou.2017.0004)05/08/2023: <https://radiopaedia.org/articles/pseudopneumoperitoneum>.